PRIMARY ORAL ULCERATIVE LESIONS

LAB 16

DR.NOOR

APHTHUS ULCER

Minor aphthous ulceration.

Minor aphthous ulceration

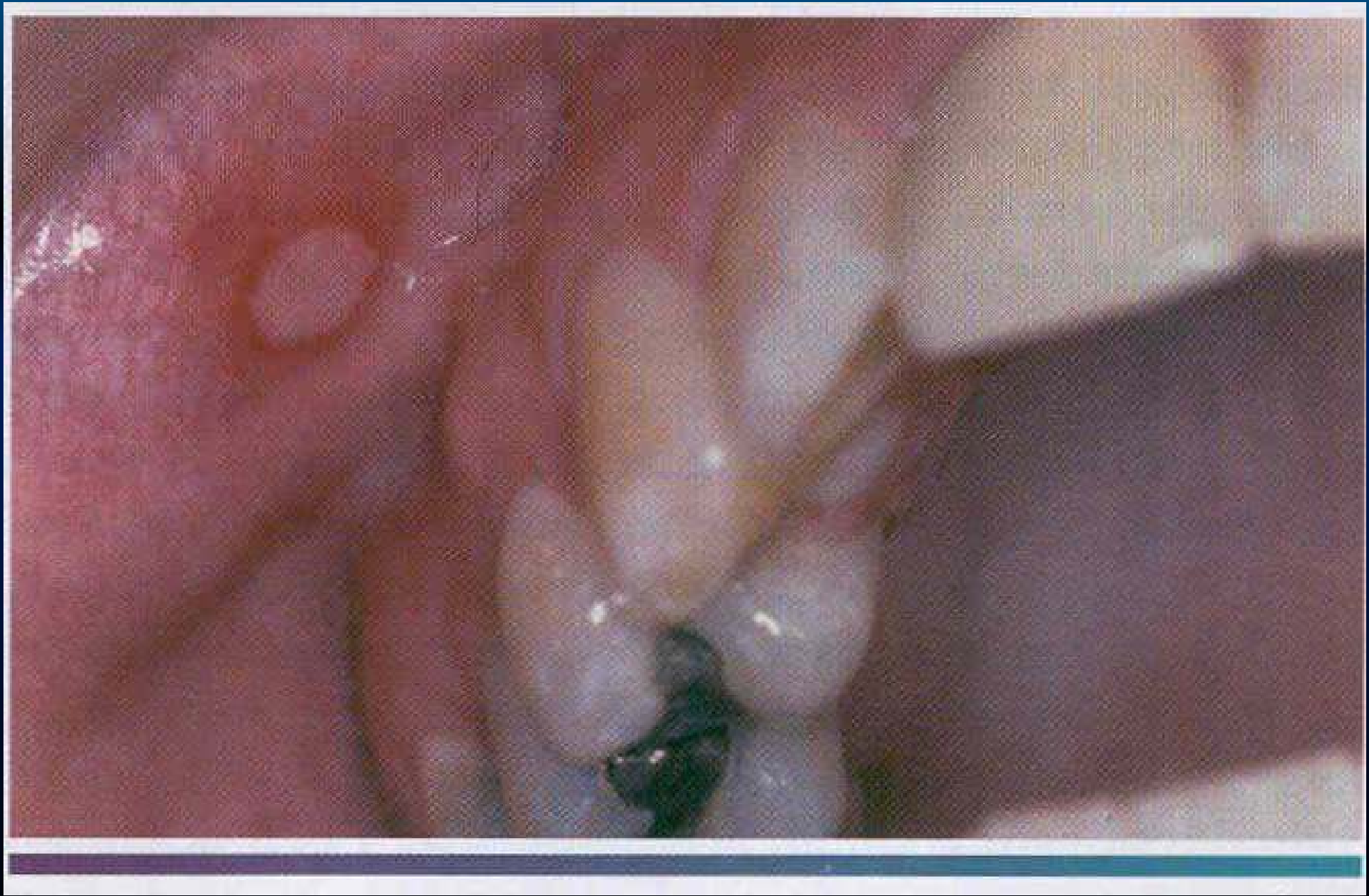

Minor aphthous ulcer

Minor aphthous ulcers .

Nodules and ulcers of crohn’s disease.

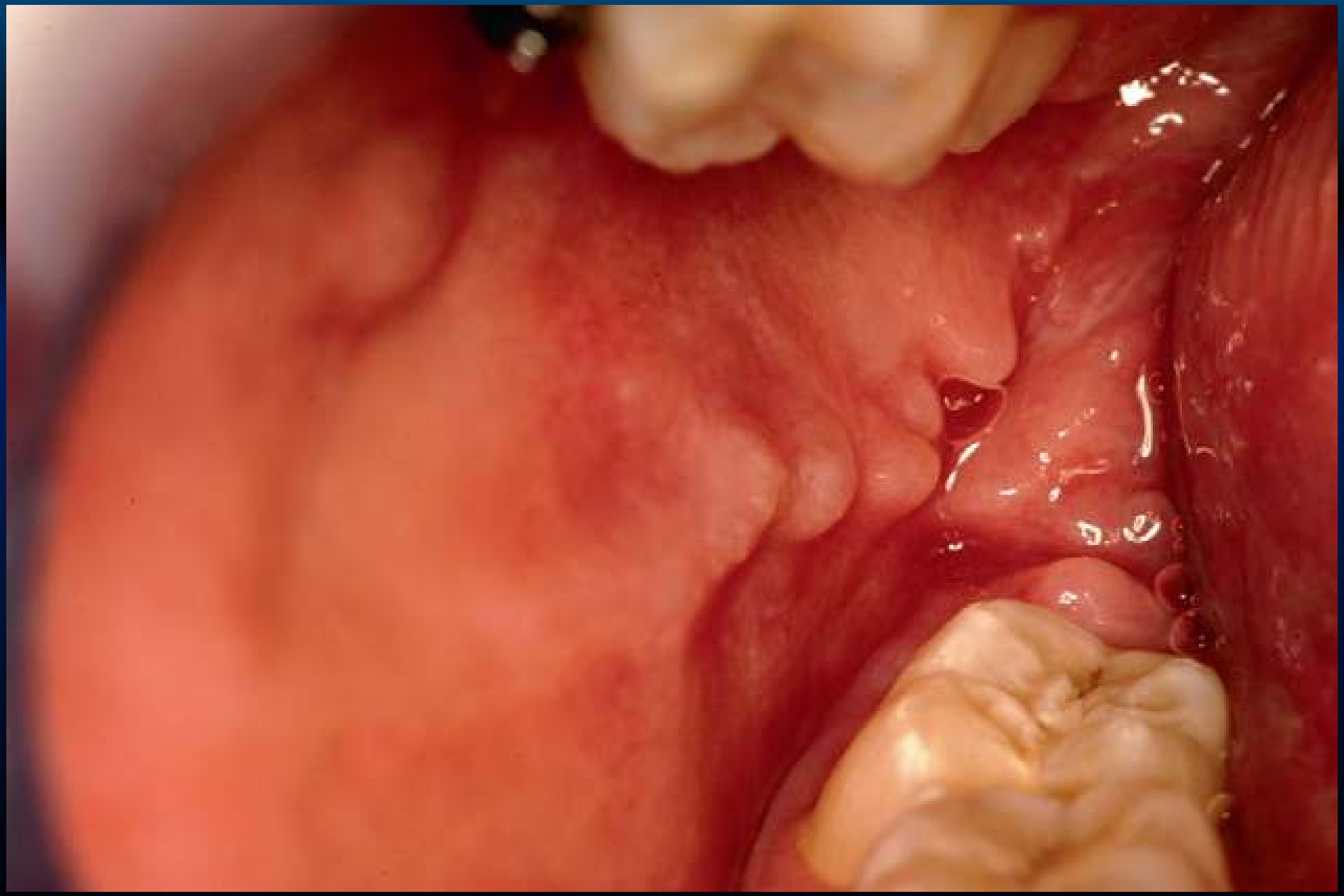

Subepithelial granuloma with multinucleated giant cells.

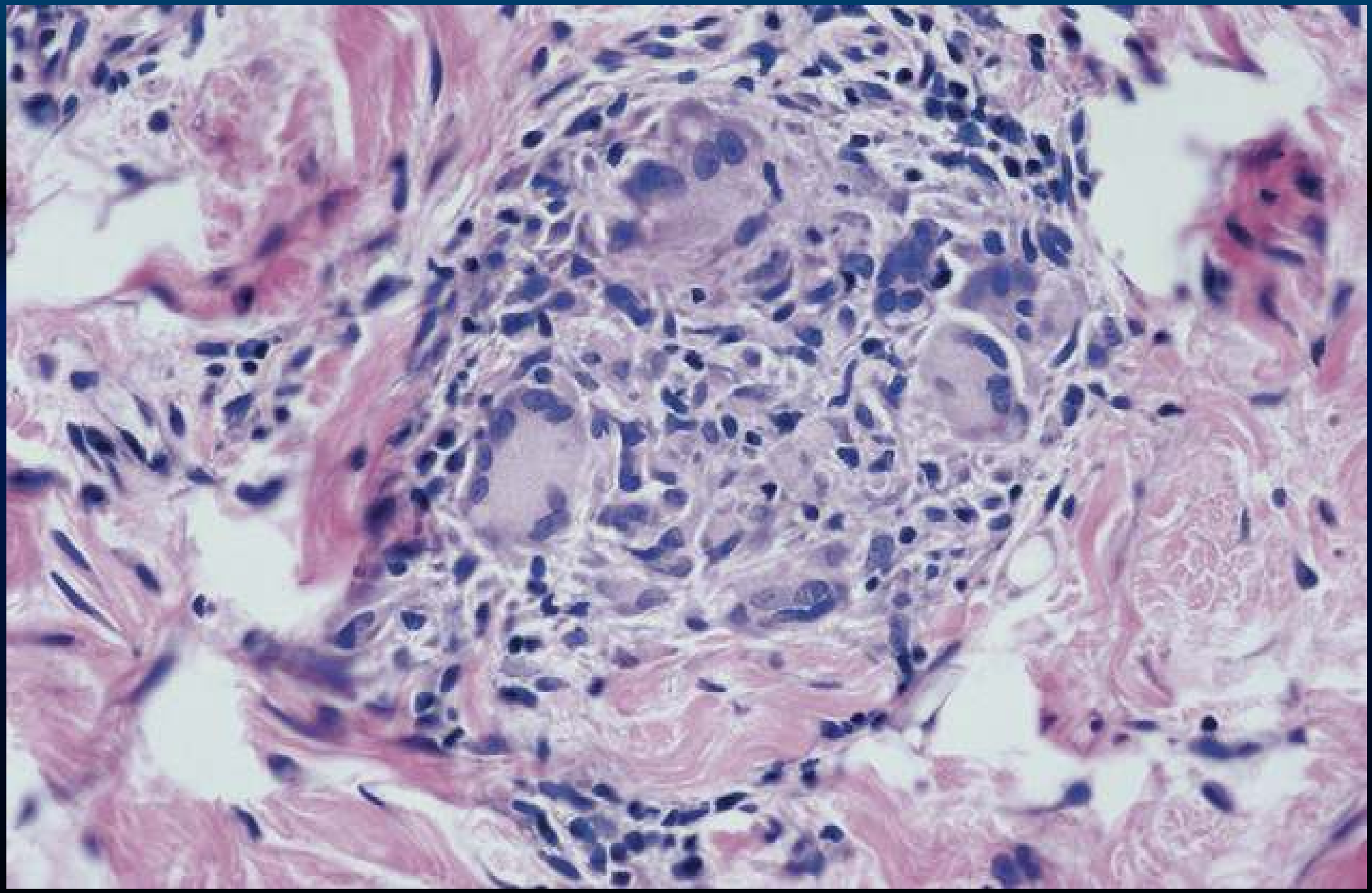

crohn’s-associated fissures in the labial vestibule.

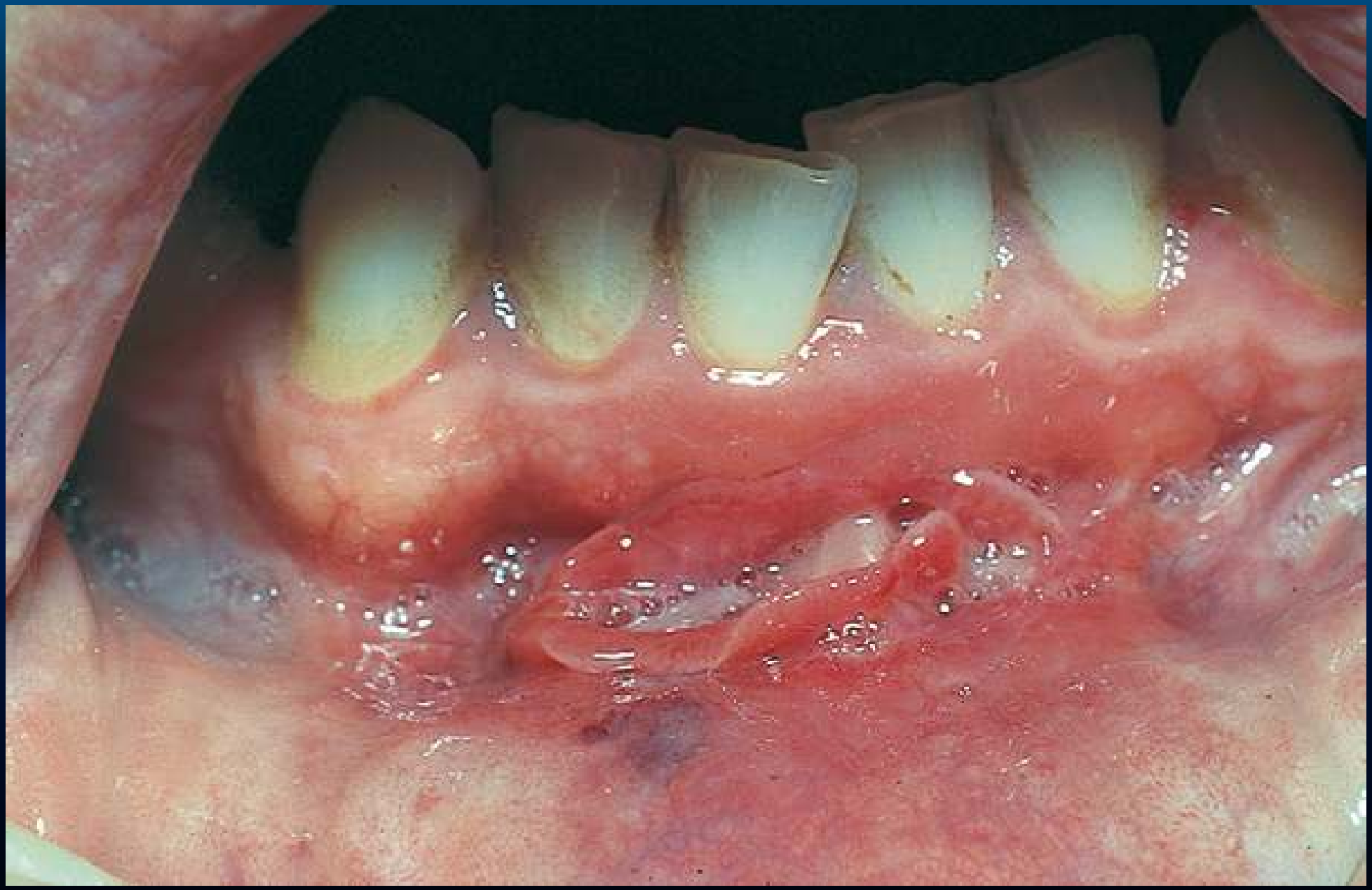

Major aphthous ulcer.

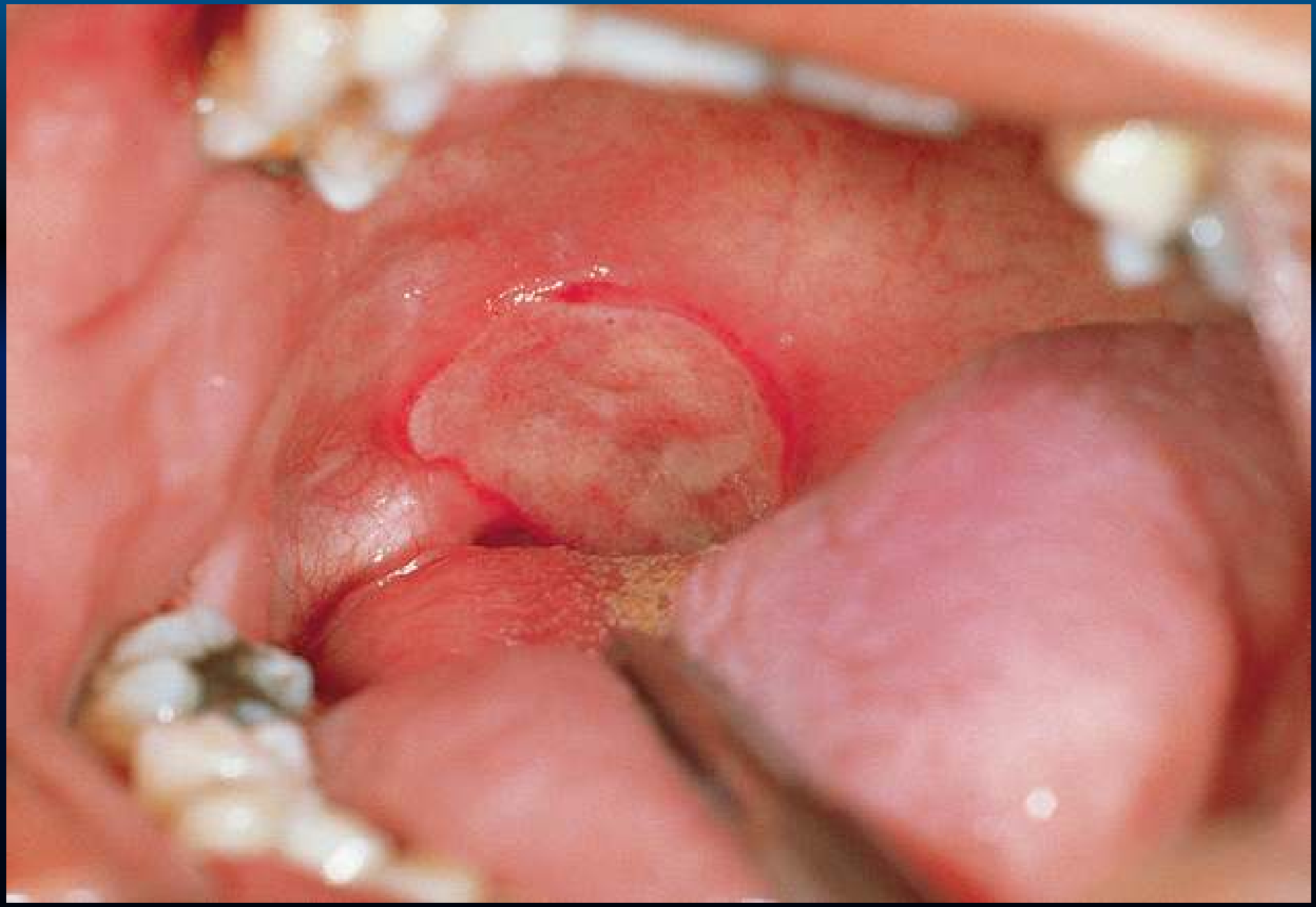

Major aphthous ulceration

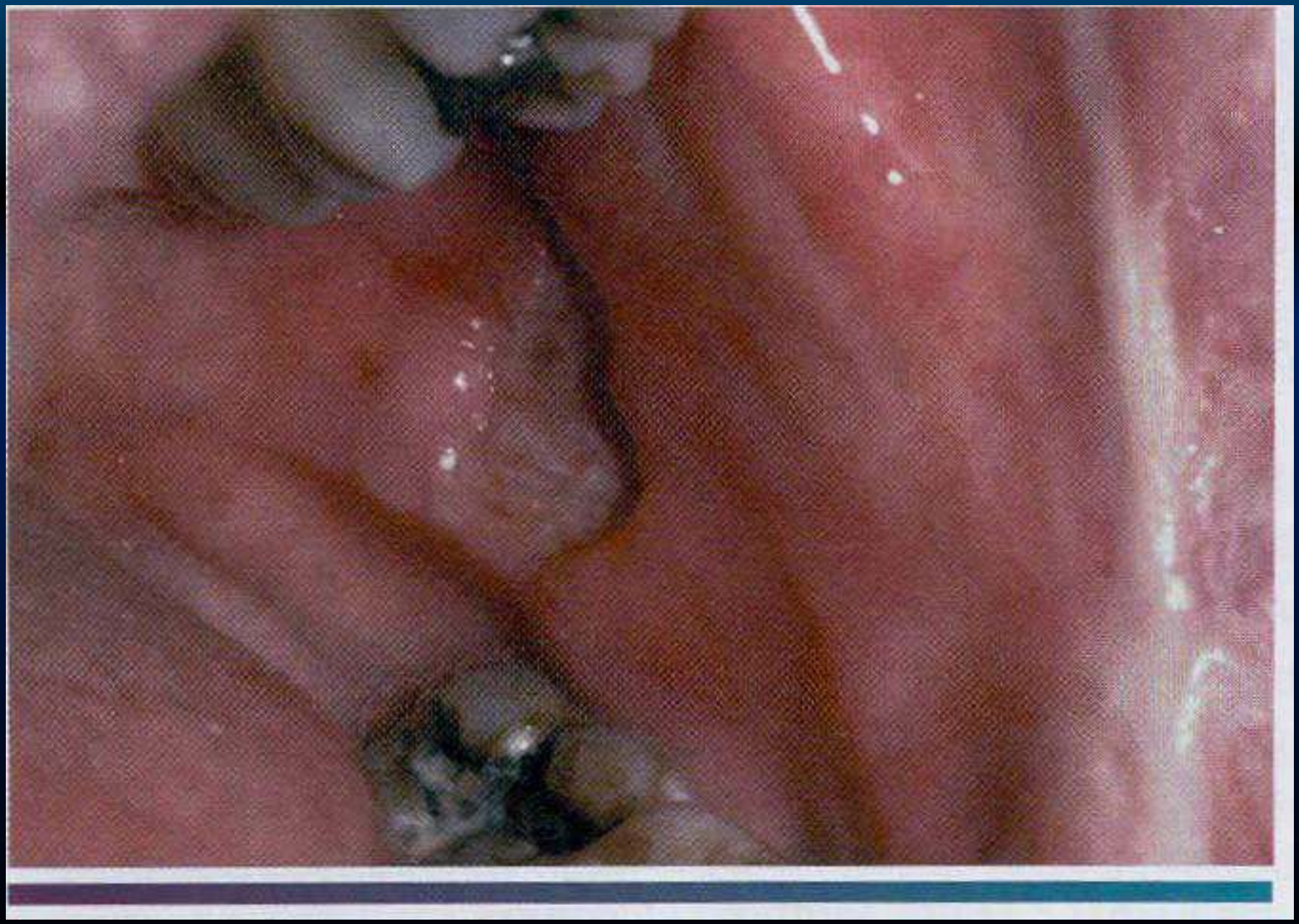

Major aphthous ulceration

Herpetiform aphthous ulcers. The patient also had numerous lesions of the lip and buccal mucosa.

Herpetiform aphthous ulcerations. Numerous pinhead ulcerations of the ventral surface of the tongue, several of which have coalesced into larger, more irregular areas of ulceration.

- **Differential Diagnosis:**
- Diagnosis of aphthous ulcers is generally based on the history and clinical appearance.
- Lesions of secondary (recurrent) oral herpes are often confused with, but usually can be distinguished from, aphthous ulcers.
- A history of vesicles preceding ulcers, location on the attached gingiva and hard palate, and crops of lesions indicate herpetic rather than aphthous ulcers.
- Other painful oral ulcerative conditions that may simulate the various forms of aphthous ulcers include trauma,

Erythema multiforme ulcers.

Erythema multiforme ulcers.

ERYTHEMA MULTIFORME ULCERS.

Erythema multiforme

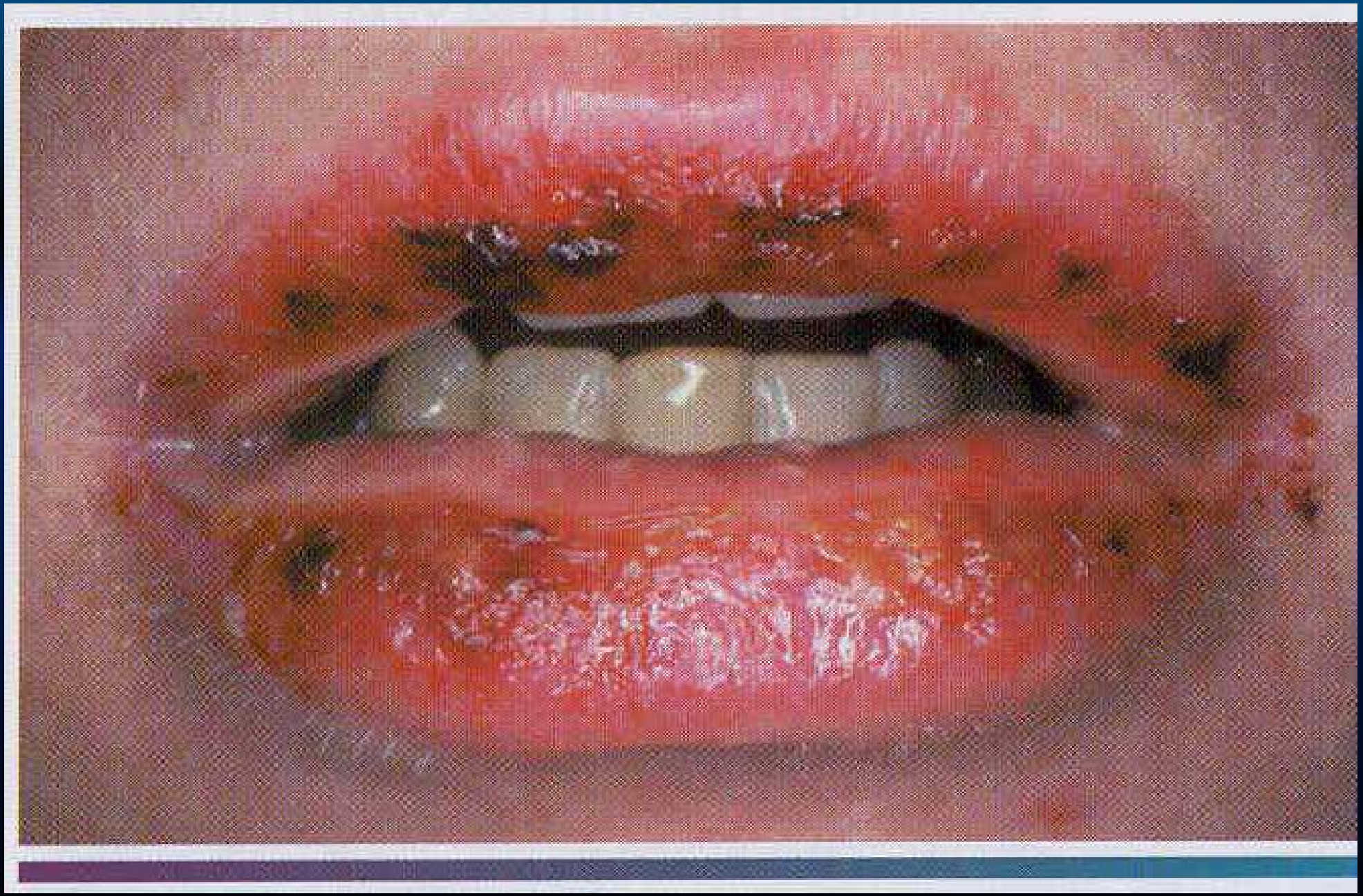

Erythema multiforme ulcers.

Erythema multiforme: Diffuse ulcerations and erosions involving the dorsal surface of this patient's tongue.

ERYTHEMA MULTIFORME CUTANEOUS TARGET LESIONS.

Erythema multiforme.

Ocular lesions in patient with erythema multiforme major.

Stevens-johnson syndrome. With erythema multiforme major (stevens-johnson syndrome), other mucosal surfaces may show involvement, such as the severe conjunctivitis depicted in this photograph.

- **Histopathology.**
- The epithelial hyperplasia and spongiosis. Basal and parabasal apoptotic keratinocytes are usually seen.
- Vesicles at the epithelium–connective tissue interface, although intraepithelial vesiculation may be seen.
- Epithelial necrosis is a frequent finding. Connective tissue changes usually appear as infiltrates of lymphocytes and macrophages in perivascular spaces and in connective tissue papillae.

oral erythema multiforme

Erythema multiforme. This medium power photomicrograph shows inf ammation and intraepithelial vesicle formation in the basilar portion of the epithelium. Numerous necrotic eosinophilic keratlnocytes are present in the blister area.

Erythema multiforme . this medium power photomicrograph shows the perivascular inflammatory infiltrate. Typically seen in erythema muitiforme.

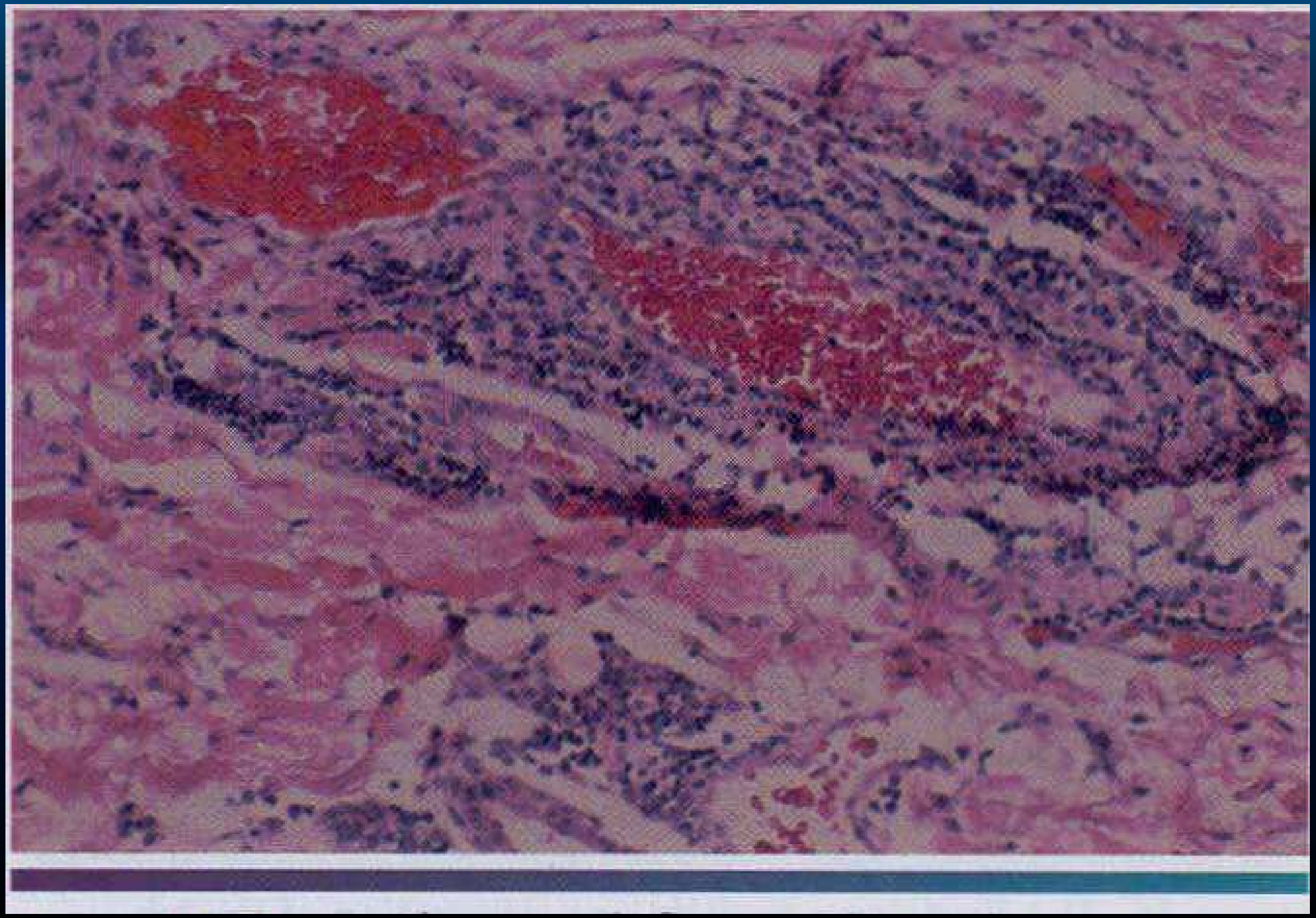

Behçet’s syndrome, oral component (aphthous ulcer).

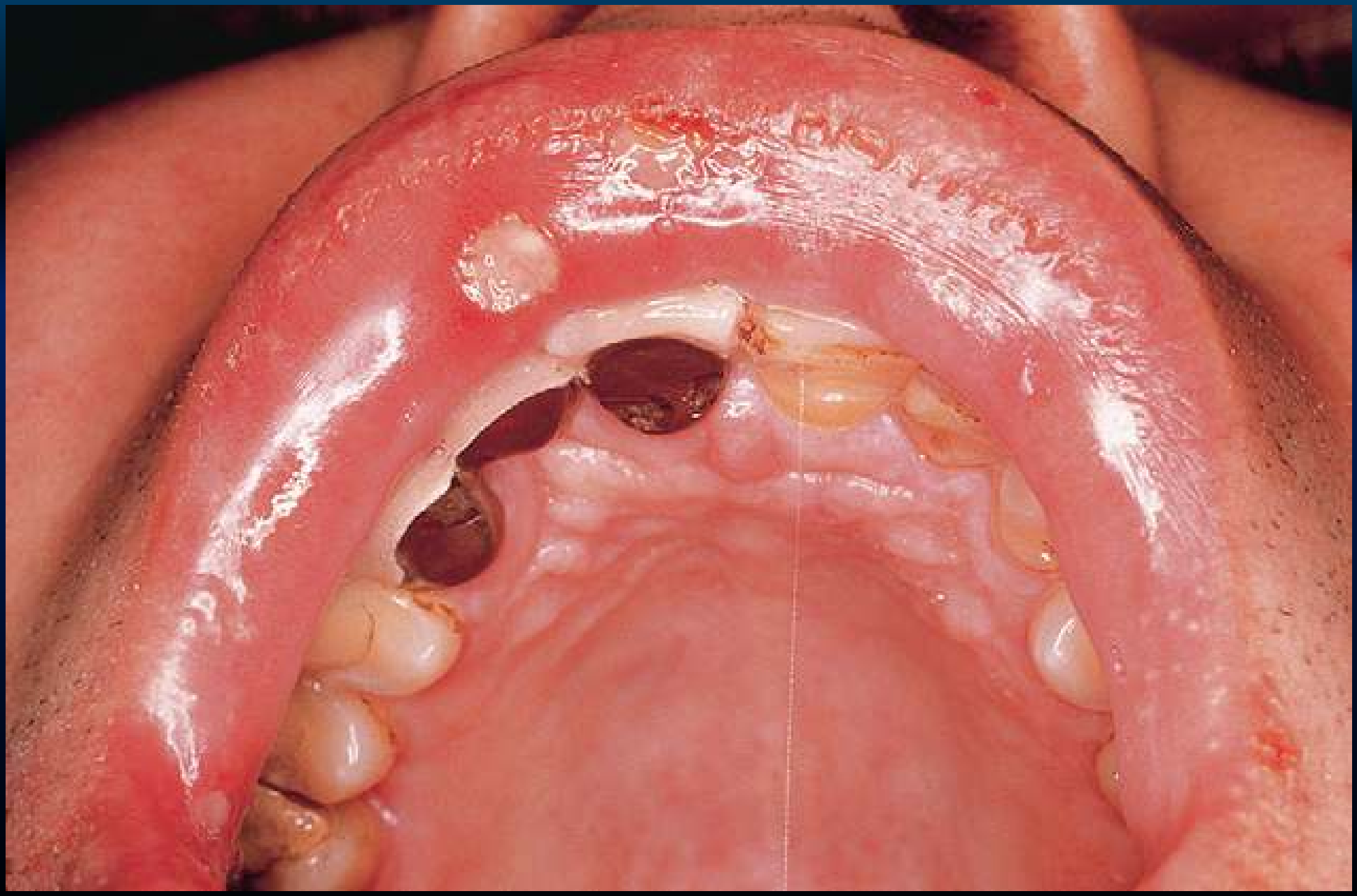

BEHÇET’S SYNDROME CONJUNCTIVITIS.

Behcet 's syndrome

Sterile pustule of the skin that developed 1 day after injection of saline. This reaction is termed cutaneous pathergy.

HISTOPATHOLOGY

- T lymphocytes are prominent in the ulcerative lesions of Behçet's syndrome.
- However, neutrophilic inf ltrates in which the cells appear within vessel walls (vasculitis) have been described.
- Immunopathologic support of a vascular target in this condition comes from the demonstration of immunoglobulins and complement within the vessel walls.

- Diagnosis. The diagnosis of Behçet's syndrome is based on clinical signs and symptoms associated with the various regions affected. No specific findings are noted in biopsy tissue, and no supportive laboratory tests are available.

- Treatment. No standard therapy is known for Behçet's syndrome. Systemic steroids are often prescribed.

Systemic Lupus Erythematosus (SLE).

This ulceration of the buccal mucosa exhibits fine radiating white striae at its periphery, clinically appearing **similar** to **erosive lichen planus**

Systemic lupus erythematosus (SLE) the erythematous patches seen in the malar regions are a characteristic

Chronic cutaneous lupus erythematosus. (Discoid lupus erythematosus)

- CCLE usually have few or no systemic signs or symptoms
- The **skin** lesions of CCLE are known as **discoid lupus erythematosus.**
- oral manifestations of CCLE **clinically identical** erosive lichen planus.
- the oral lesions of CCLE rarely occur in the absence of skin lesions.
- An ulcerated or atrophic, erythematous central zone, surrounded by white, fine, radiating striae

Systemic lupus erythematosus (SLE) . Irregularly shaped ulcerations of the buccal mucosa.

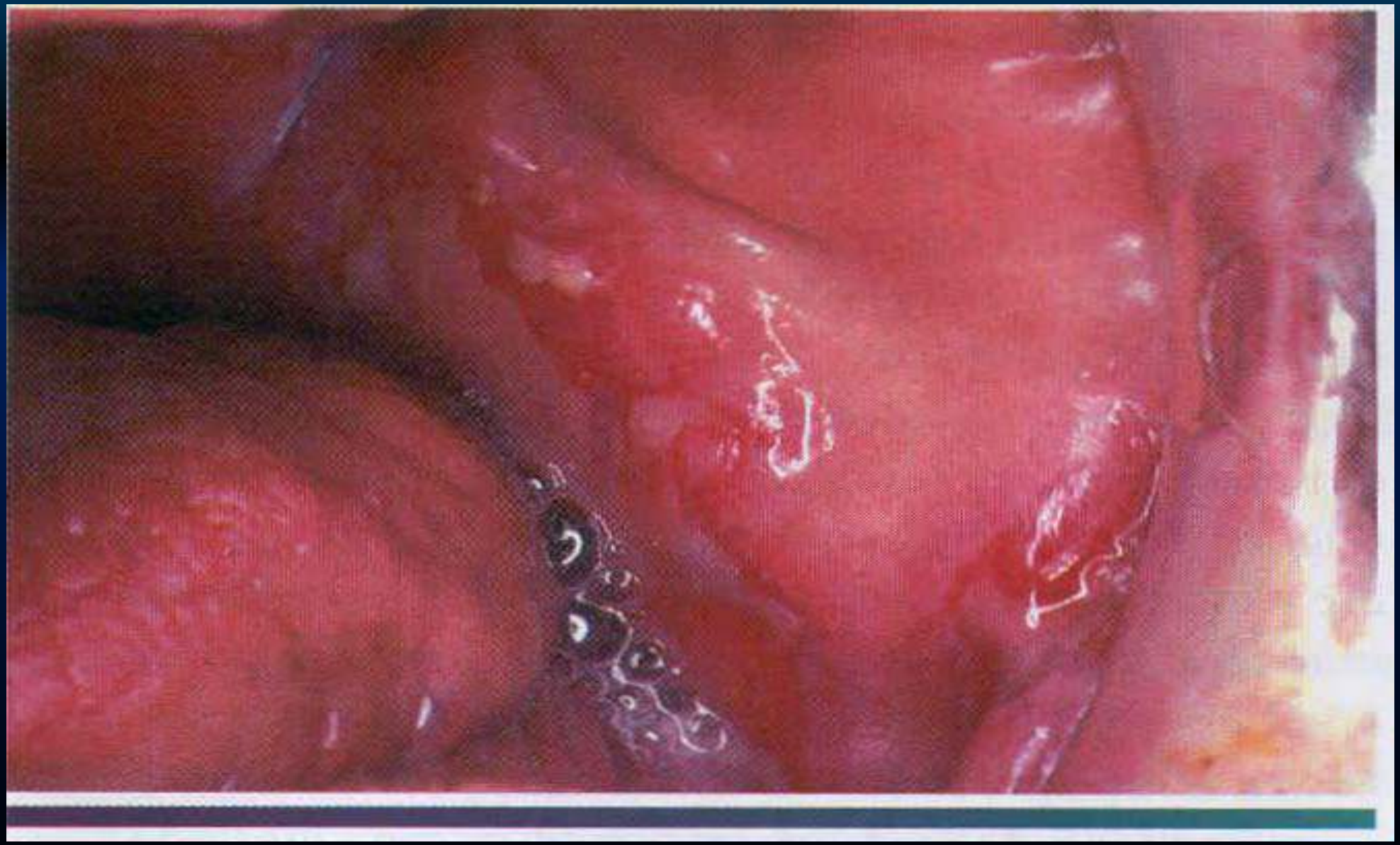

Chronic cutaneous lupus erythematosus (ccle). The skin lesions are characterized by scaling, atrophy, and pigmentary disturbances, which are most evident on sun exposed skin.

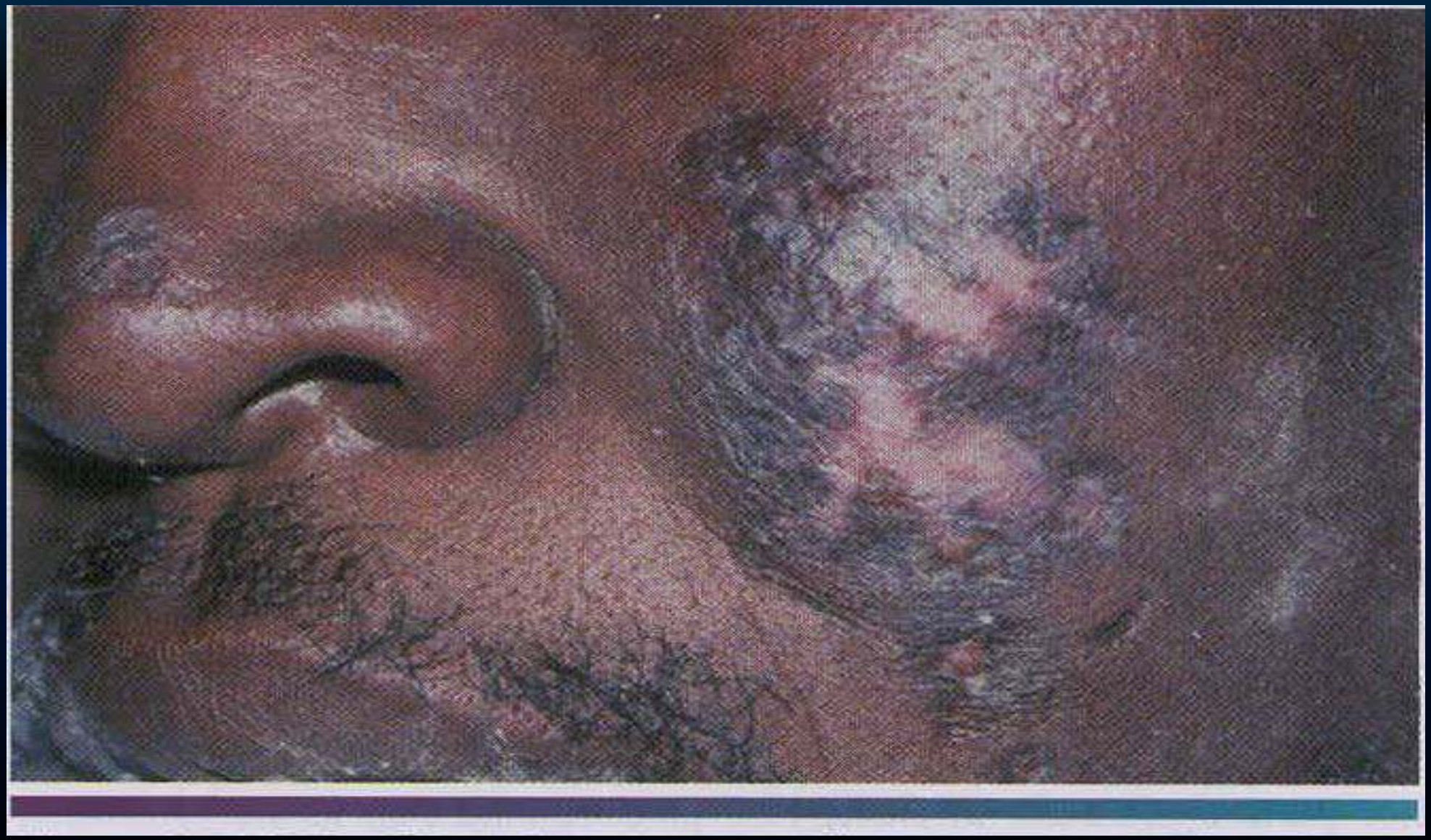

Erythematous zones
of the buccal mucosa are surrounded by radiating keratotic striae,
these features are similar to those of erosive lichen planus.

Histopathologic Features

The **skin lesions** of CCLE are characterized by hyperkeratosis, often displaying keratin packed into the openings of hair follicles ("follicular plugging").

In all forms of lupus erythematosus, **degeneration of the basal cell layer**, and the underlying connective tissue supports patchy to dense aggregates of chronic inflammatory cells.

in the deeper connective tissue, the inflammatory infiltrate often surrounds the small blood vessels.

- The oral lesions demonstrate hyperkeratosis, alternating atrophy and thickening of the spinous cell layer, **degeneration of the basal cell layer**, and subepithelial lymphocytic infiltration . (same L.P)
- 1-presence patchy deposits of a periodic acid-Schiff (PAS)-positive material in the basement membrane zone,
- 2-subepithelial edema (sometimes to the point of vesicle formation), and a more diffuse, deep inflammatory infiltrate, often in a perivascular orientation.
- differentiating lichen planus from lupus erythematosus is **best** done by direct immunofluorescence studies **or** histopathologic examination of the cutaneous lesions.

Lupus erythematosus (LE) . low-power photomicrograph showing hyperparakeratosis with interface mucositis and perivascular inflammation

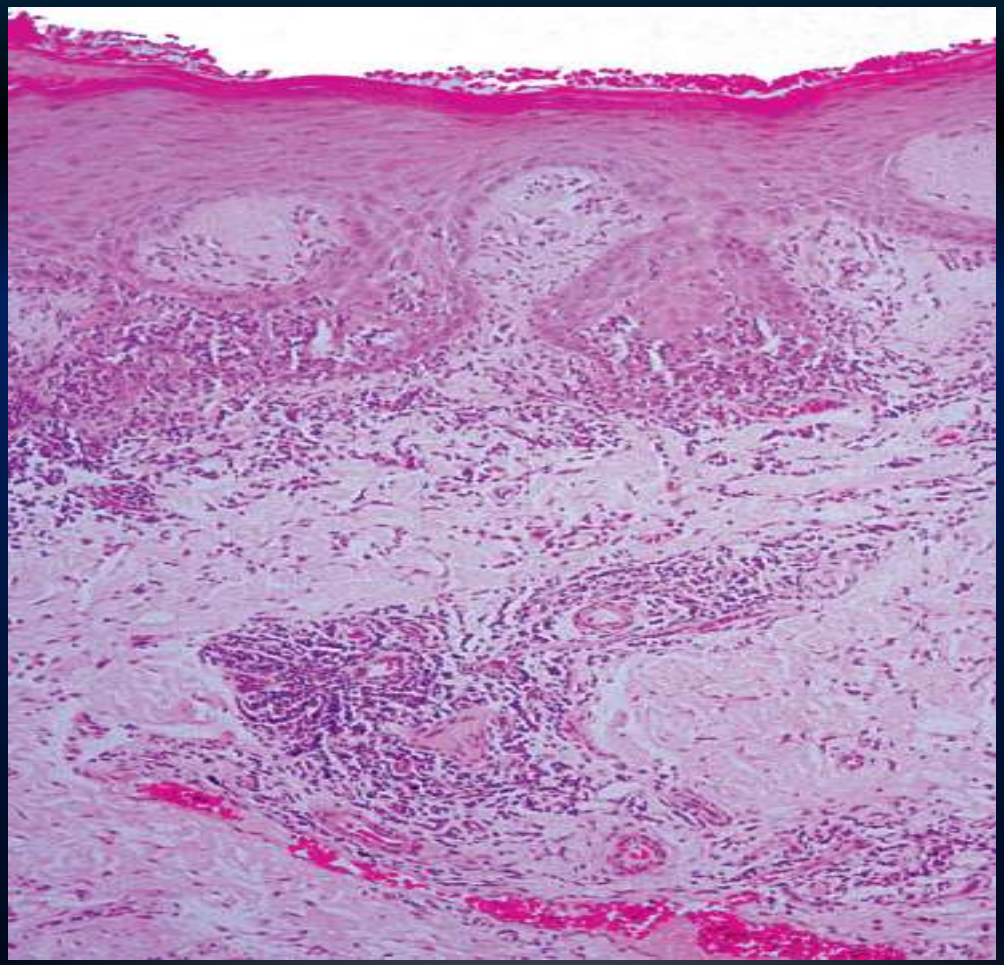

Diagnosis

Direct immunofluorescence testing of lesional tissue shows deposition of one or more immunoreactants (usually IgM, IgG, or C3) in a shaggy or granular band at the basement membrane zone.

In addition. direct immunofluorescence testing of clinically normal skin of SLE patients often shows a similar deposition of IgG, IgM, or complement components.

This finding is known as **a positive lupus band test** .

Evaluation of serum obtained from a patient with SLE shows various immunologic abnormalities.

DISCOID (CHRONIC) LUPUS ERYTHEMATOSUS.

DISCOID LUPUS ERYTHEMATOSUS OF THE LIP.

DISCOID LUPUS ERYTHEMATOSUS OF THE FACE.

- **Histopathologic Features traumatic ulcerations**
- Simple traumatic ulcerations are covered by a fibrinopurulent membrane that consists of fibrin intermixed with neutrophils.
- The ulcer bed consists of granulation tissue that supports a mixed inflammatory infiltrate of lymphocytes, histiocytes, neutrophils, and, occasionally, plasma cells.

- In patients with **eosinophilic ulcerations** (traumatic ulcerative granuloma with stromal eosinophilia [TUGSE])
- The pattern is very similar; however, the inflammatory infiltrate extends into the deeper tissues and exhibits sheets of lymphocytes and histiocytes intermixed with eosinophils.
- In addition, the vascular connective tissue deep to the ulceration may become hyperplastic and cause surface elevation.

chronic ulcer showing fibrin covering an inflamed granulation tissue base.

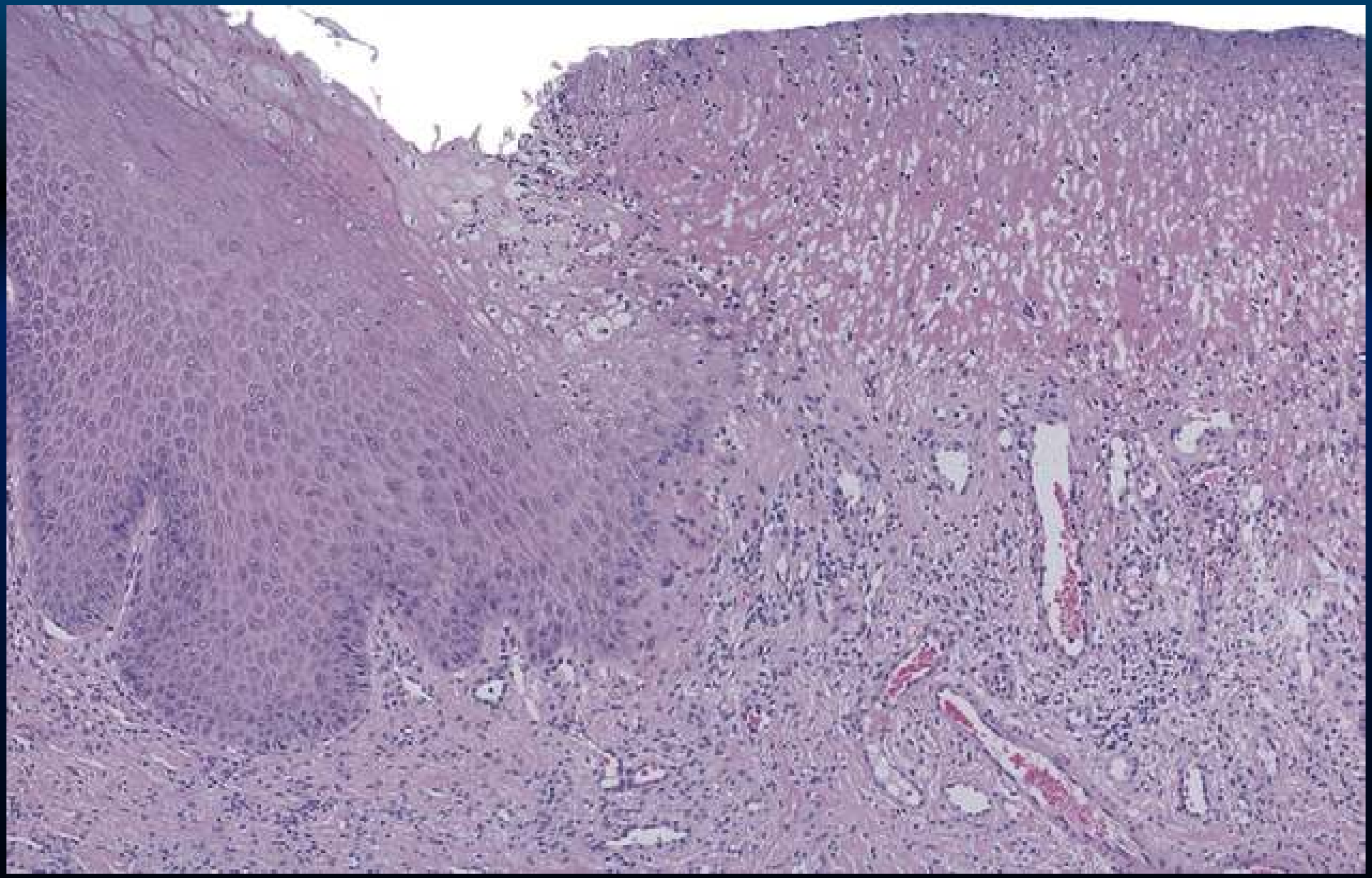

Chronic ulcer showing fibrin covering an inflamed granulation tissue base.

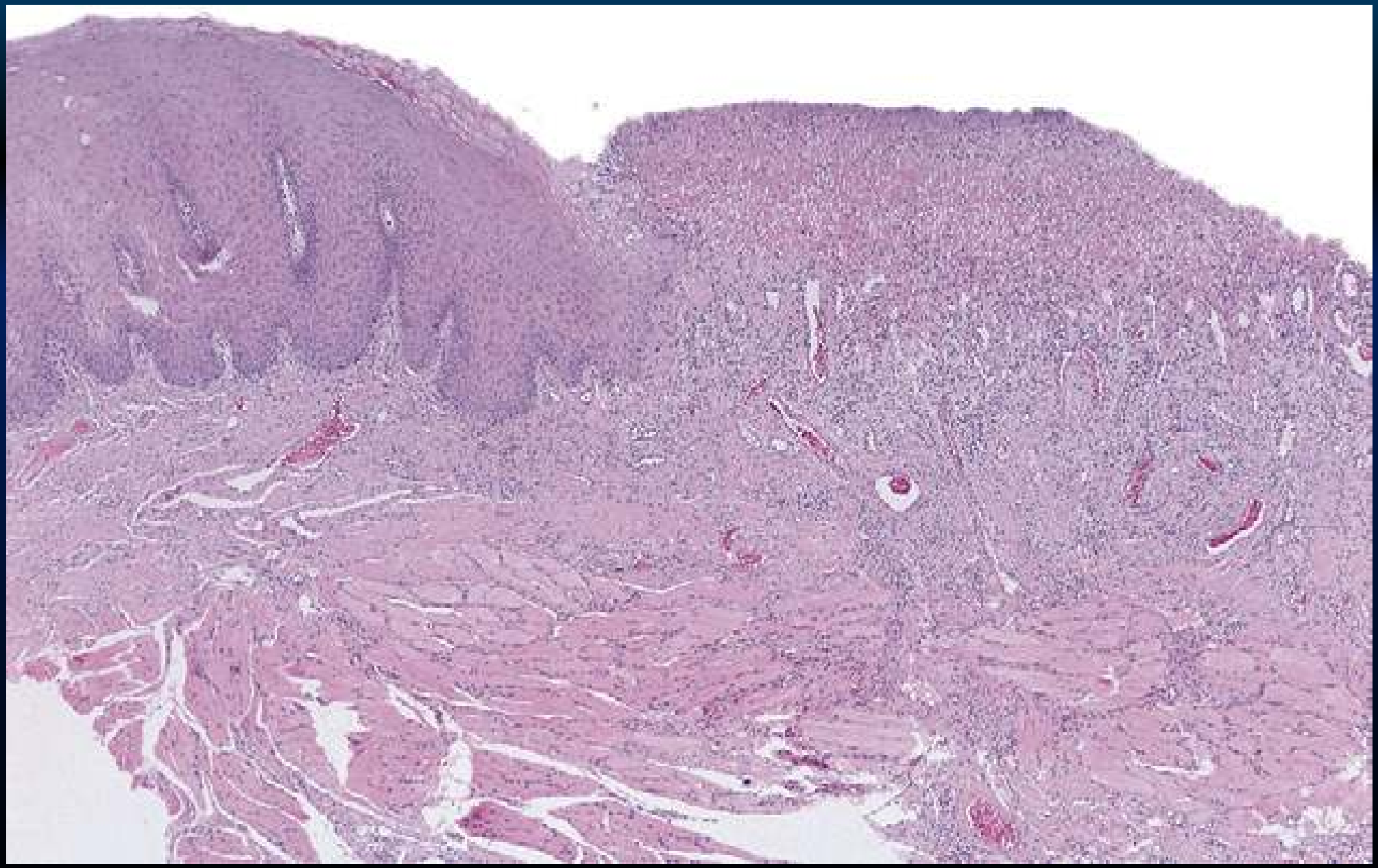

ACUTE TRAUMATIC ULCER.

Acute ulcer of the floor of mouth (saliva ejector injury).

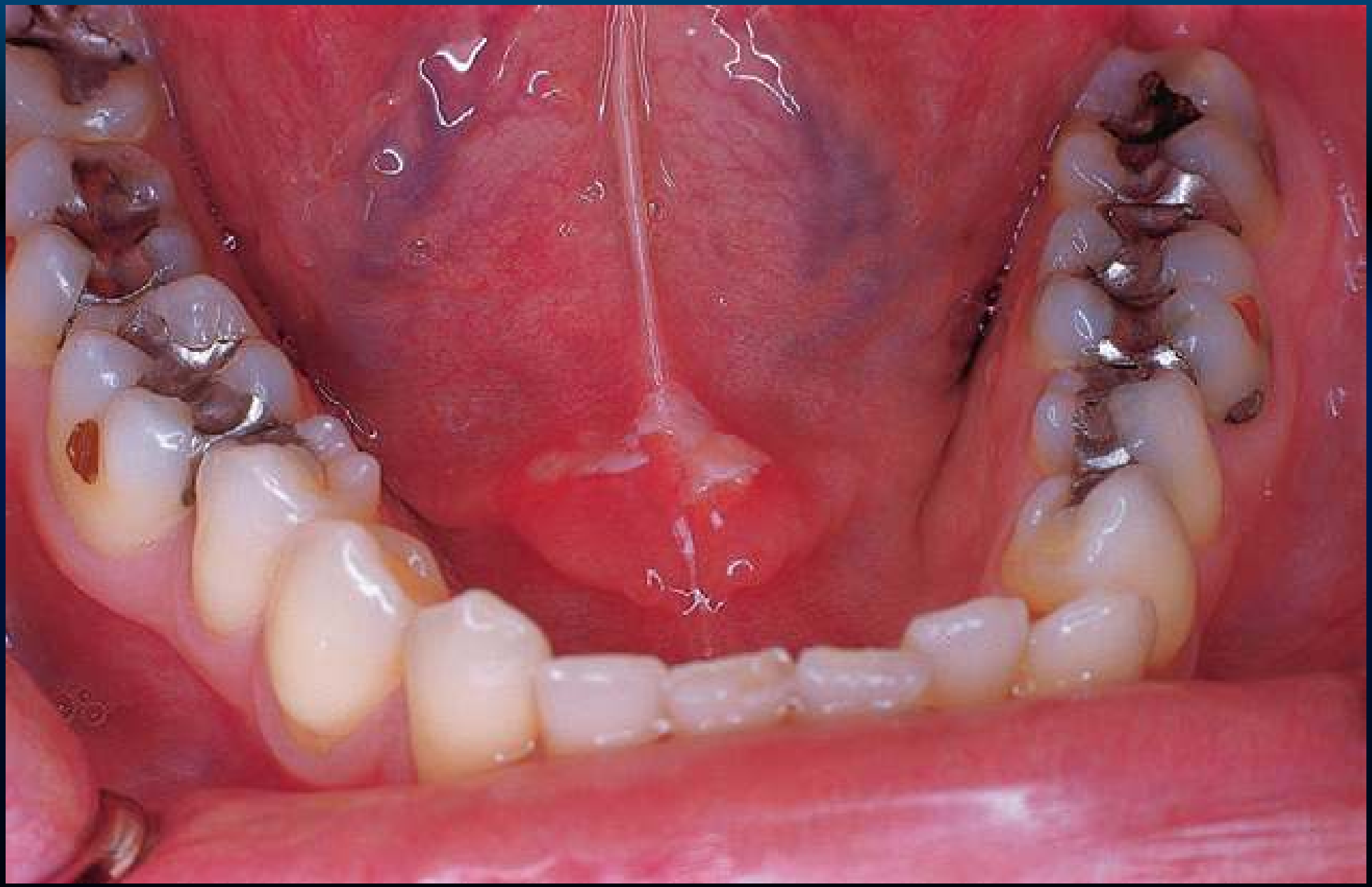

Anesthesia-associated acute tongue ulcer.

Chronic ulcer of the lateral tongue.

Chronic ulcer of the palate.

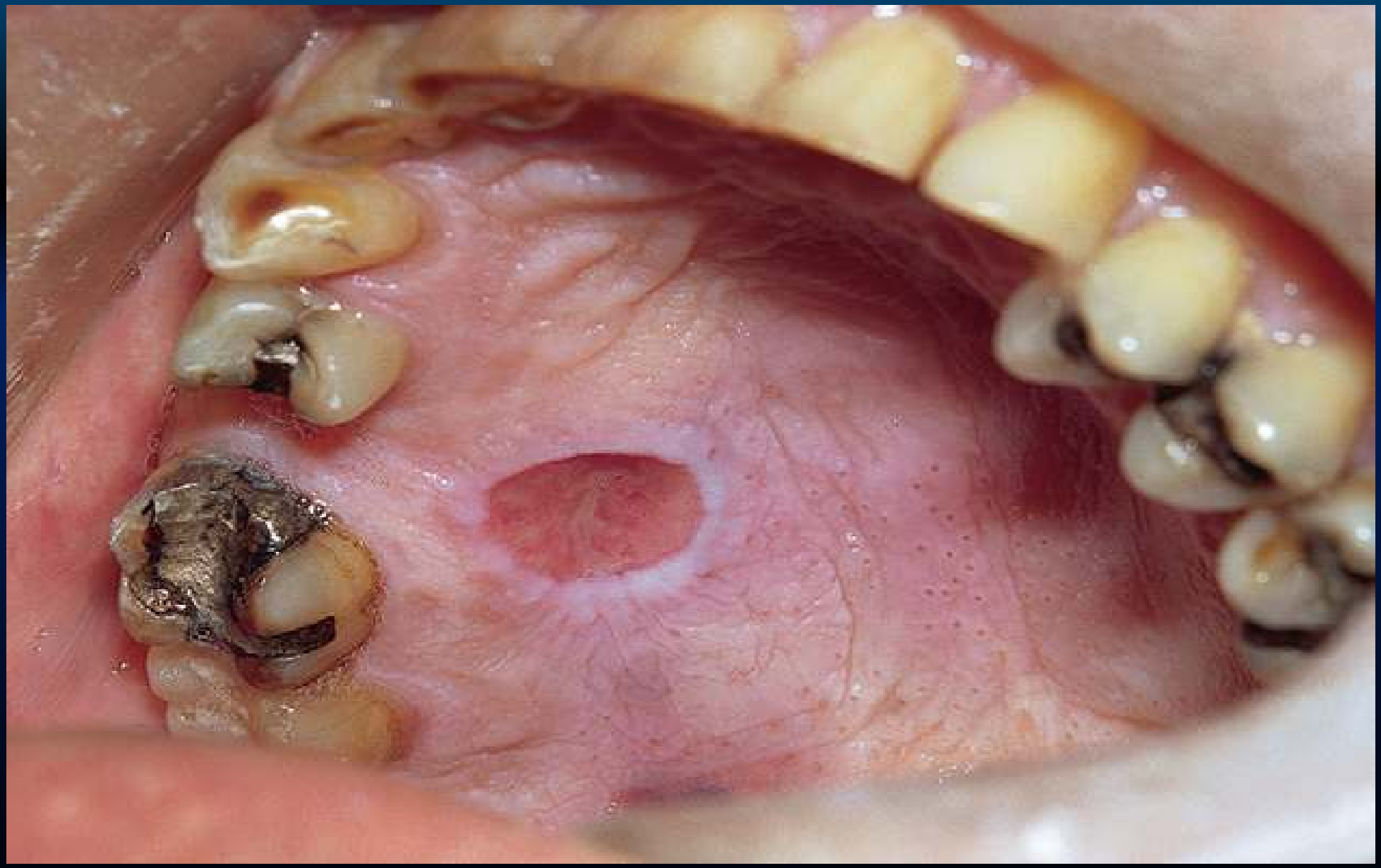

Ulcers and erythema caused by a denture flange.

TRAUMATIC GRANULOMA.

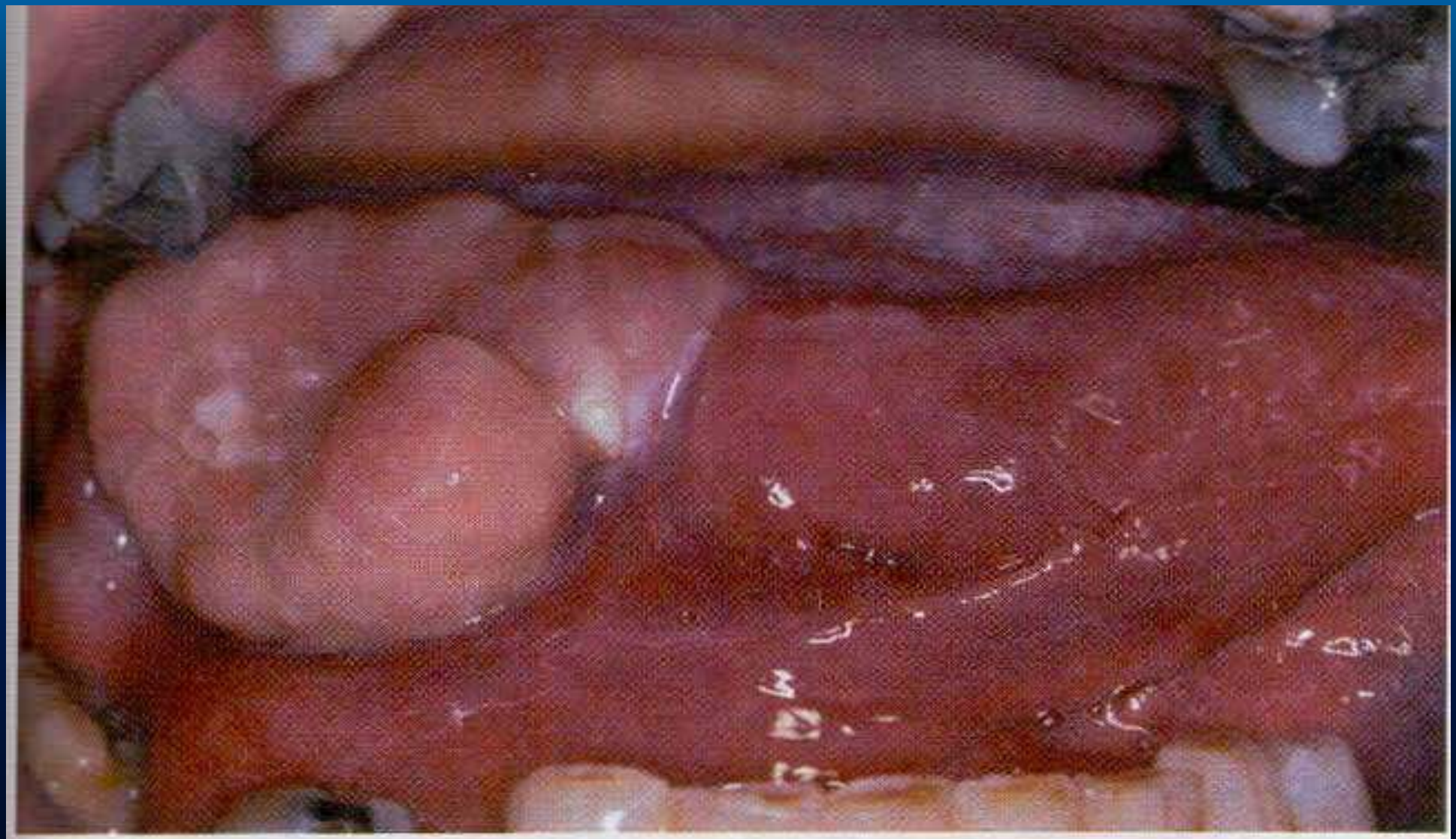

Figure 8-9 • **Traumatic granuloma.** Ulceration of lateral border of the tongue on the right side. The surface of the ulcer developed proliferative granulation tissue that resembles a pyogenic granuloma.

TRAUMATIC ULCERATION.

MUCOSAL ULCERATION WITH A HYPERKERATOTIC COLLAR LOCATED ON THE VENTRAL SURFACE OF THE TONGUE

TRAUMATIC GRANULOMA.

EXOPHYTIC ULCERATED MASS ON VENTROLATERAL TONGUE ASSOCIATED WITH MULTIPLE JAGGED TEETH.

Eosinophilic ulceration .

Initial presentation of a large ulceration of the dorsal surface of the tongue.

Significant resolution noted 2 weeks after incision al biopsy.

Subsequent healing noted 4 weeks after biopsy

- # TREATMENT AND PROGNOSIS

- The irritating cause should be removed.
- A topical anesthetic or protective film (hydroxypropyl cellulose films) can be applied for temporary pain relief.
- If the cause is not obvious, or if a patient does not respond to therapy, then **biopsy is indicated**.
- Rapid healing after a biopsy is typical even with large eosinophilic ulcerations, Recurrence is not expected.
- The use of corticosteroids in the management of traumatic ulcerations is controversial.
- Some clinicians have suggested that use of such medications may delay healing.
- Inspite of this, other investigators have reported success using corticosteroids to treat chronic traumatic ulcerations.